

# Rectus abdominalis muscle metastasis from uterine leiomyosarcoma: An unusual case and review of the literature

Tayfun Güngör<sup>1</sup>, Serap Akbay<sup>2</sup>, Hayri Aksüt<sup>3</sup>, Bülent Yılmaz<sup>3</sup>

<sup>1</sup>Department of Obstetrics and Gynecology, Zekai Tahir Burak Women's Health Education and Research Hospital, Ankara, Turkey

<sup>2</sup>Department of Pathology, Zekai Tahir Burak Women's Health Education and Research Hospital, Ankara, Turkey

<sup>3</sup>Department of Obstetrics and Gynecology, İzmir Katip Çelebi University Atatürk Education and Research Hospital, İzmir, Turkey

## Abstract

Uterine leiomyosarcoma is an aggressive malignancy. Spread to the lung, thyroid, liver, brain, pancreas, heart, duodenum, breast, vagina, submandibular gland, and bone has been reported. We describe a case of metastatic uterine leiomyosarcoma to the rectus abdominalis muscle as the first case in the literature. A 39-year-old nulligravid woman presented with a history of pelvic pain. Physical examination discovered about a 6-cm mass in the suprapubic region. She had previously undergone a hysterectomy for uterine leiomyosarcoma. Operative findings had revealed a mass measuring 4×5×6 cm located in the rectus abdominalis muscle. Abnormal mitotic figures and necrosis were evident, and uterine leiomyosarcoma was diagnosed. Uterine leiomyosarcomas are malignancies of the smooth muscle arising from the myometrium. Skeletal muscle is an uncommon site of metastasis by hematogenous spread. In conclusion, we have described a case of skeletal muscle metastasis (first case of rectus abdominalis muscle metastasis) secondary to uterine leiomyosarcoma. (J Turk Ger Gynecol Assoc 2014; 15: 122-4)

**Key words:** Uterine leiomyosarcoma, metastasis, skeletal muscle, rectus abdominalis muscle

**Received:** 06 May, 2013

**Accepted:** 06 October, 2013

## Introduction

Leiomyosarcomas are malignant tumors of smooth muscle, and it constitutes 5% of soft tissue sarcomas (1, 2). It is diagnosed in 1.3% of all uterine malignancies (3). The disease is most commonly detected in 30-40-year-old age groups, and the prevalence is much higher in black women and European-American Jews than other women (4).

The symptoms of disease are associated with the tumor size and location. However, vaginal bleeding and abdominal pain are mostly common. (5). The tumor primarily metastasizes hematogenously. Spread to the lung (6), thyroid (7), liver (6, 8), brain (9), and bone (6, 10) has been reported. To the best of our knowledge, there are two cases of skeletal muscle metastasis of uterine leiomyosarcoma reported in the literature (5, 11).

In this case report, we describe a case of metastatic uterine leiomyosarcoma to the rectus abdominalis muscle as the first case in the literature.

## Case Presentation

A 39-year-old multigravid woman presented with a history of pelvic pain and mass. She had hypertension and had no family history of cancer and other chronic diseases. Previously,

she had undergone myomectomy for leiomyoma that was confirmed by pathological examination. After the surgery, she had in vitro fertilization (IVF) treatment, but she had no successful pregnancy. After IVF treatment failure, she underwent another surgery for uterine myoma, and pathologic investigation revealed leiomyosarcoma, and she was referred to our hospital.

She underwent total abdominal hysterectomy, bilateral salphingo-oophorectomy and bilateral pelvic paraaortic lymph node dissection and appendectomy at our hospital in December, 2005. There was no abnormality in the pelvis or the other abdominal organs and anterior abdominal wall in the immediate exploration. All the lymph nodes were confirmed as reactive lymph nodes by pathological examination. The patient was again admitted to our hospital with a complaint of a suprapubic mass and pelvic pain in March 2006. Physical examination discovered a round, well-circumscribed, movable, firm, and painless mass of about 6 cm in the suprapubic region. Moreover, transvaginal ultrasonography (Picker 9100, Hitachi Medical Ltd, Tokyo, Japan) showed a hypoechoic mass measuring 61x39 mm at the widest diameters anterior to the urinary bladder (Figure 1). This mass could also be a local inoculation; however, the odds for a hematogenous dissemination are higher. Operative findings of a second



surgery had revealed a myomatous mass measuring 4x5x6 cm located in the rectus abdominalis muscle. The mass could not totally extracted from the rectus abdominalis muscle, and histopathological examination revealed that the polypoid tissue was highly cellular and composed of pleomorphic spindle cells with hyperchromatic nuclei (Figure 2). Abnormal mitotic figures and necrosis were evident, and uterine leiomyosarcoma was diagnosed (Figure 3).

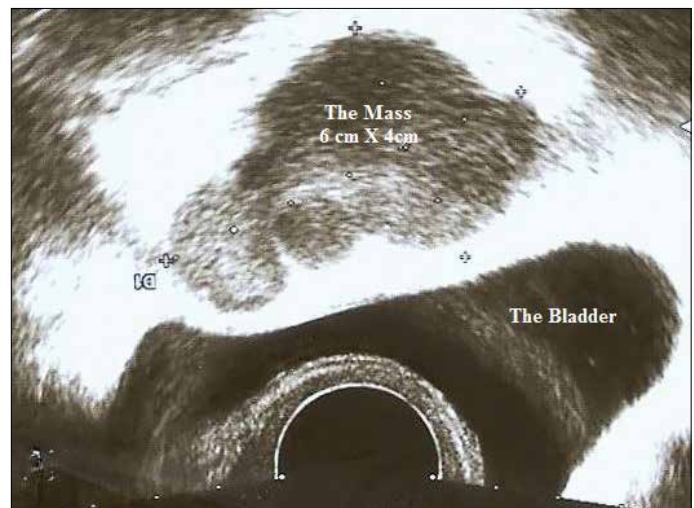
Her follow-up abdominal magnetic resonance imaging (MRI) (Intera 1.5 T, Philips Medical Systems, France) 1 month after surgery revealed a 3.5x2.5x2 cm mass in the left rectus abdominalis muscle, and chest X-ray showed 90x35 mm of opacity. With those findings, she underwent 25 cures in total of 50 gr external abdominal radiotherapy and 6 cures of chemotherapy of Adriamycin 100 mg (Pfizer, New York, USA), Haloxan 3 gr (Baxter, Deerfield, USA), and mesna 3 gr (Bedford Laboratories, Bedford, USA). The patient was informed, and informed consent was obtained. The patient was still alive and decided to have her follow-up in another hospital; so, we do not have any information about the fate of the mass anterior of the bladder, and she was lost to follow-up.

## Discussion

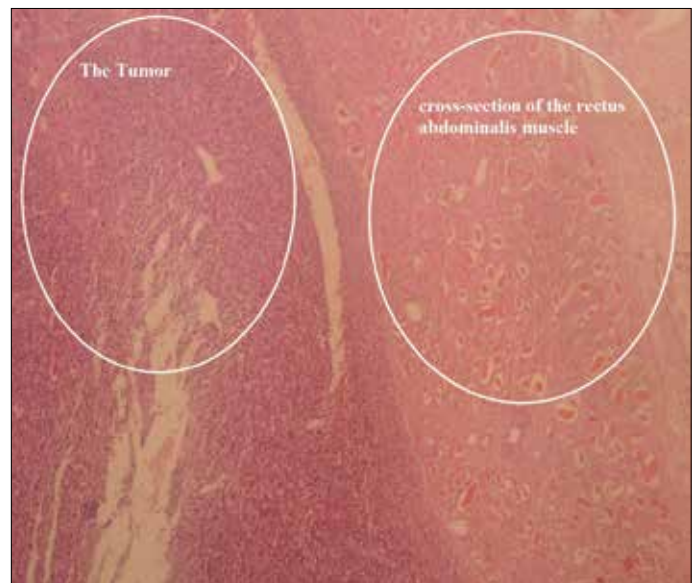
Leiomyosarcoma of the uterus originates from the myometrium (5). Uterine leiomyosarcomas constitute 25%-35% of uterine sarcomas and 1% of uterine malignancies (12). It usually occurs de novo, but in some cases, a history of prior irradiation may be present (5). The tumor spreads most commonly by hematogenous route to the lung (6), thyroid (7), liver (6, 8), brain (9), and bone (6, 10). Bronchogenic carcinoma, breast carcinoma, melanoma, and gastrointestinal and urinary tract tumors commonly metastasize to skeletal muscle, but it is an unexpected site of metastasis of leiomyosarcoma (5). It has a poor prognosis because of its high recurrence and metastasis (13). Salazar et al. (12, 14) reported 5-year survival of leiomyosarcomas of stage I of 53% and stage II-IV of 8%, respectively.

Up to date, 5 cases of skeletal muscle metastasis of leiomyosarcoma have been reported (5, 11, 15-17). O'Brein et al. (5) presented a case of a 68-year-old patient with a complaint of painless mass in the anterior aspect of the thigh. She had undergone a hysterectomy 3 years ago for dysfunctional uterine bleeding. Leiomyosarcoma was confirmed by pathological examination. The patient had radiotherapy and chemotherapy. After 2 years of surgery, a metastatic solitary lesion was found in the liver and treated with radiofrequency ablation. Following 1 year of a recurrence-free period, the patient presented with an enlarging mass in her thigh region. MRI scan revealed 2 discrete masses in the rectus femoris and gracilis muscle. Histological examination of both lesions showed intermediate-grade leiomyosarcoma.

Nusrath et al. (11) presented a case of a 65-year-old female with a mass in the left cheek. It was enlarging for 3 weeks. Physical examination showed a discrete, tender mass in the left masseter muscle and an enlarged preauricular lymph node. The fine needle aspiration result was suspected squamous cell carcinoma. A wide local excision was performed, and histopathology and immunohistochemical stains revealed a tumor that was positive for desmin antibodies with mitotic figures. Computed tomography (CT) scan of the chest was performed and was negative for any tumors. A further excision was performed, and



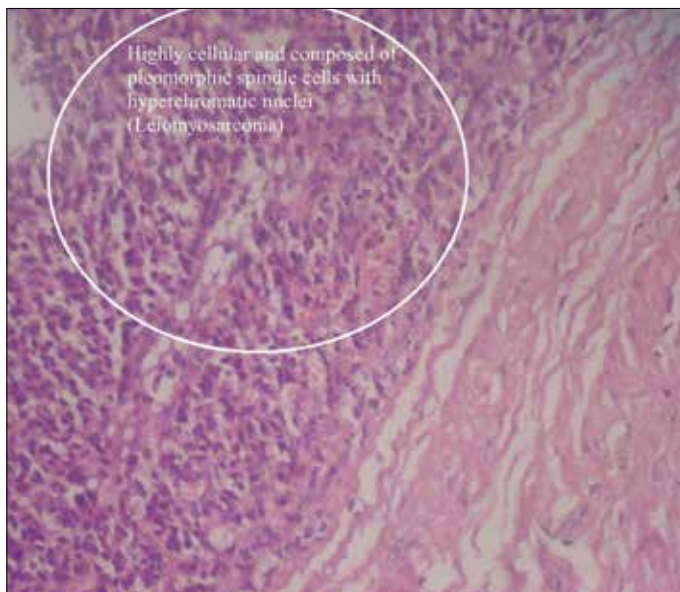
**Figure 1. Transvaginal ultrasound image: “A hypoechoic mass measuring 61x39 mm at the widest diameters anterior to the urinary bladder”**



**Figure 2. A photomicrograph of the pathological specimen (H&E, x40): Metastatic leiomyosarcoma infiltrating the skeletal muscles**

the patient was followed up with CT scans of the neck region. But, the patient had a complaint of suprapubic discomfort during the follow-up period. An ultrasound was performed and showed a pelvic mass originating from the uterus or ovary. Laparotomy was performed. At the laparotomy, they found a large unresectable retroperitoneal mass that was adherent to the small bowel, which on biopsy showed a leiomyosarcoma; so, chemotherapy was given to the patient.

Aslan et al. (15) presented a case of a 76-year-old female with a gross mass in the right temporal region. Two years before presentation, she had been operated on for a primary uterine leiomyosarcoma. She had not received any post-operative radiotherapy or chemotherapy. Physical examination revealed a gross mass, nearly 10 cm in maximum diameter, in the right temporal region of the scalp. She was operated on, and the



**Figure 3. A photomicrograph of the pathological specimen: Uterine leiomyosarcoma (H&E, x200): Cellular eosinophilic spindle cell tumor with nuclear atypia and mitosis**

mass was totally excised together with the temporalis muscle. On histopathological evaluation, it was composed of spindle-shaped atypical mesenchymal cells, which showed 10-12 mitoses/10 high-power fields with marked pleomorphism and central cigar-shaped nuclei arranged in fascicles. The tumor morphology was interpreted as high-grade (III) leiomyosarcoma.

Cappellani et al. (16) treated a 61-year-old woman for mesocolon leiomyosarcoma by radical resection of left nephrectomy and left hemicolectomy. Three years after the surgery, a leiomyosarcoma of the duodenal wall was diagnosed, and she underwent pancreatoduodenectomy. Three months later, a mass was observed rapidly growing to a diameter of 4 cm over 1 month. The histological examination revealed metastasis from high-grade leiomyosarcoma. The patient underwent chemotherapy treatment. The patient experienced progression of disease with multiple pulmonary and encephalic metastases 5 months later.

Courtney et al. (17) presented a case of a 52-year-old female with a metastatic uterine leiomyosarcoma to the left flank 10 years following total abdominal hysterectomy for a left primary adnexal mass. Leiomyosarcomas rarely metastasize to the flank or skeletal muscle. The majority of the recurrences occurs within 8 to 16 months after hysterectomy. The case offers an atypical recurrence of this malignancy.

In the present case, the patient had a diagnosis of leiomyoma of the uterus and had undergone myomectomy. Pathology had shown a benign lesion. But, in a short period, she again had surgery for a similar complaint, but at that time, the histological result was malignant. There may be a rapid progression to leiomyosarcoma or misdiagnosis of the previous mass excised. In conclusion, we present a case of metastasis of uterine leiomyosarcoma to the rectus abdominalis muscle for the first time in the literature. Therefore, skeletal muscle metastasis should be kept in mind in the management of such malignancies.

**Ethics Committee Approval:** N/A.

**Informed Consent:** Written informed consent was obtained from patient who participated in this case.

**Peer-review:** Externally peer-reviewed.

**Author contributions:** Concept - B.Y., T.G., H.A., S.A.; Design - B.Y., H.A.; Supervision - T.G., B.Y.; Resource - H.A., S.A.; Materials - B.Y., H.A., S.A.; Data Collection&/or Processing - B.Y., H.A.; Analysis&/or Interpretation - B.Y., H.A.; Literature Search - B.Y., H.A., S.A.; Writing - B.Y., H.A.; Critical Reviews - T.G., B.Y.

**Conflict of Interest:** No conflict of interest was declared by the authors.

**Financial Disclosure:** The authors declared that this study has received no financial support.

## References

1. Blanchard DK, Budde JM, Hatch GF, Wertheimer-Hatch L, Hat KF, Davis GB, et al. Tumors of the small intestine. *World J Surg* 2000; 24: 421-9. [\[CrossRef\]](#)
2. Enzinger FM, Weiss SW. Leiomyosarcoma. In: Enzinger FM, editor. *Soft Tissue Tumors*. St Louis: Mosby; 1988. p. 402-21.
3. Schwartz LB, Diamond MP, Schwartz PE. Leiomyosarcomas: Clinical presentation. *Am J Obstet Gynecol* 1993; 36: 652-9.
4. Botwin KP, Zak PJ. Lumbosacral radiculopathy secondary to metastatic uterine leiomyosarcoma. *Spine* 2000; 25: 884-7. [\[CrossRef\]](#)
5. O'Brien JM, Brennan DD, Taylor DH, Holloway DP, Hurson B, O'Keane JC, Eustace SJ. Skeletal muscle metastasis from uterine leiomyosarcoma. *Skeletal Radiol* 2004; 33: 655-9. [\[CrossRef\]](#)
6. Rose PG, Piver MS, Tsukada Y, Lau T. Patterns of metastasis in uterine sarcoma. An autopsy study. *Cancer* 1989; 63: 935-8. [\[CrossRef\]](#)
7. Leath CA 3rd, Huh WK, Straughn JM Jr, Conner MG. Uterine leiomyosarcoma metastatic to the thyroid. *Obstet Gynecol* 2002; 100: 1122-4. [\[CrossRef\]](#)
8. Soyer P, Riopel M, Bluemke DA, Scherrer A. Hepatic metastases from leiomyosarcoma: MR features with histopathologic correlation. *Abdom Imaging* 1997; 22: 67-71. [\[CrossRef\]](#)
9. Wronski M, de Palma P, Arbit E. Leiomyosarcoma of the uterus metastatic to brain: case report and a review of the literature. *Gynaecol Oncol* 1994; 54: 237-41. [\[CrossRef\]](#)
10. Nanassis K, Alexiadou-Rudolf C, Tsitsopoulos P. Spinal manifestation of metastasizing leiomyosarcoma. *Spine* 1999; 24: 987-9. [\[CrossRef\]](#)
11. Nusrath MA, Kendall CH, Avery CM. Metastatic uterine leiomyosarcoma masquerading as a primary lesion of the masseter muscle. *Int J Oral Maxillofac Surg* 2006; 35: 466-8. [\[CrossRef\]](#)
12. Salazar OM, Dunne ME. The role of radiation therapy in the management of uterine sarcomas. *Int J Radiat Oncol Biol Phys* 1980; 6: 899-902. [\[CrossRef\]](#)
13. Iwamoto I, Fujino T, Higashi Y, Tsuji T, Nakamura N, Komokata T, Douchi T. Metastasis of uterine leiomyosarcoma to the pancreas. *J Obstet Gynaecol Res* 2005; 31: 531-4. [\[CrossRef\]](#)
14. Salazar OM, Bonfiglio TA, Patten SF, Keller BE, Feldstein M, Dunne ME, Rudolph J. Uterine sarcomas: Natural history, treatment, and prognosis. *Cancer* 1978; 42: 1152-60. [\[CrossRef\]](#)
15. Aslan E, Kuzeyli K, Cakir E, Reis A. Temporalis muscle metastasis of the uterine leiomyosarcoma: A case report. *Turk Neurosurg* 2008; 18: 215-8.
16. Cappellani A, Di Vita M, Lo Menzo E, Zanghi A, Lanzafame S, Veroux P, et al. Muscular metastasis from mesocolic and duodenal leiomyosarcoma. A case report and a review of the literature. *Ann Ital Chir* 2011; 82: 383-7.
17. Courtney MW, Levine EA. Uterine leiomyosarcoma metastatic to soft tissue of the flank following a ten-year disease-free interval. *South Med J* 2009; 102: 325-6. [\[CrossRef\]](#)