

Step-by-step laparoscopic excision of cervical stump for persistent CIN and bleeding in a postmenopausal patient without uterine manipulator

✉ Candost Hanedan, ✉ Şahin Kaan Baydemir, ✉ Vakkas Korkmaz

Clinic of Obstetrics and Gynecology, Division Gynecologic Oncology, University of Health Sciences Türkiye, Ankara Etlik City Hospital, Ankara, Türkiye

Abstract

A 51-year-old woman presented with two years of postmenopausal spotting, mainly postcoital. Although vaginal atrophy was considered, prior use of vaginal estrogen at another center had not improved her symptoms. She had a history of persistent human papillomavirus (HPV) 16 infection and abnormal cytology. Initial colposcopy showed CIN 1 but one year later, a biopsy revealed CIN 2, and loop electrosurgical excision procedure (LEEP) was performed with negative margins. At 6-month follow-up, HPV positivity and low-grade squamous intraepithelial lesion persisted, with CIN 2 on colposcopy. Despite being offered repeat LEEP, the patient opted for definitive surgery. Due to a family history of ovarian cancer, she also requested bilateral salpingo-oophorectomy. This case highlights an individualized approach to recurrent cervical dysplasia and postmenopausal bleeding. Despite long-term follow-up, cervical dysplasia persisted, necessitating surgical intervention. The procedure was completed laparoscopically without complications. Cervical stump excision is a rare but important option in patients experiencing persistent symptoms or premalignant lesions after subtotal hysterectomy (SH). This case highlights careful patient selection and thorough counseling regarding potential long-term risks, including bleeding, dysplasia, and cervical malignancy, following SH. [J Turk Ger Gynecol Assoc. 2026; 27(2): 154-6]

Keywords: Cervical stumpectomy, minimally invasive surgery, spotting, subtotal hysterectomy

Received: 22 April, 2025 **Accepted:** 05 October, 2025 **Epub:** 28 October, 2025 **Publication Date:** June 02, 2026

Introduction

This video article reports a case of cervical stumpectomy and bilateral salpingo-oophorectomy in a patient with a history of subtotal hysterectomy (SH).

Case report

A 51-year-old patient, who had undergone an emergency postpartum SH 20 years previously due to hemorrhage, presented with persistent postmenopausal spotting ongoing for two years predominantly following sexual intercourse. Although vaginal atrophy was considered as a potential cause,

she had previously used vaginal estrogen prescribed at another medical center without resolution of symptoms. Her cervical pathology history included persistent human papillomavirus (HPV) 16 positivity and abnormal cervical cytology findings. A colposcopy performed three years earlier due to a finding of atypical squamous cells of undetermined significance (ASCUS) revealed CIN 1; a follow-up co-test one year later again showed HPV positivity and ASCUS, and colposcopic biopsy confirmed CIN 2, for which a loop electrosurgical excision procedure (LEEP) was performed with negative surgical margins. At her 6-month follow-up, due to ongoing symptoms, repeat testing revealed continued HPV positivity and low-grade squamous



Address for Correspondence: Şahin Kaan Baydemir
e-mail: drkaanbydmr@gmail.com **ORCID:** orcid.org/0000-0002-0511-925X
DOI: 10.4274/jtgga.galenos.2025.2025-4-5

Cite this article as: Hanedan C, Baydemir ŞK, Korkmaz V. Step-by-step laparoscopic excision of cervical stump for persistent CIN and bleeding in a postmenopausal patient without uterine manipulator. J Turk Ger Gynecol Assoc. 2026; 27(2): 154-6

The study was presented as an oral presentation at MIJID Congress 2024 in Türkiye.



Copyright© 2026 The Author(s). Published by Galenos Publishing House on behalf of Turkish-German Gynecological Association. This is an open access article under the Creative Commons Attribution-NonCommercial-NoDerivatives 4.0 (CC BY-NC-ND) International License.

intraepithelial lesion, with colposcopy showing CIN 2. Despite being offered another LEEP procedure, the patient declined and opted for definitive surgical treatment. Given a family history of ovarian cancer in a first-degree relative, she also requested bilateral salpingo-oophorectomy. Hormonal profile showed estradiol < 20 pg/mL and follicle-stimulating hormone 48 mIU/mL, confirming postmenopausal status. The patient was scheduled for laparoscopic cervical stumpectomy and bilateral salpingo-oophorectomy. Written informed consent was obtained for both the surgical procedure and the use of all relevant clinical data and video documentation for publication.

Surgical technique

The surgical procedure was performed laparoscopically. The procedure involved the insertion of a 10-mm trocar from the umbilicus, two 5-mm trocars from the right side, and one 5-mm trocar from the left side. Adhesions resulting from prior surgical interventions were carefully dissected. The retroperitoneum was entered in a patient who was both clinically and biochemically menopausal, for bilateral oophorectomy. The

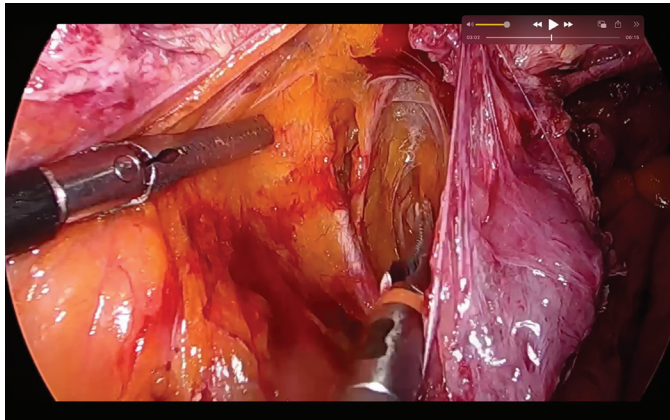


Figure 1. Uterine artery originating from the internal iliac artery

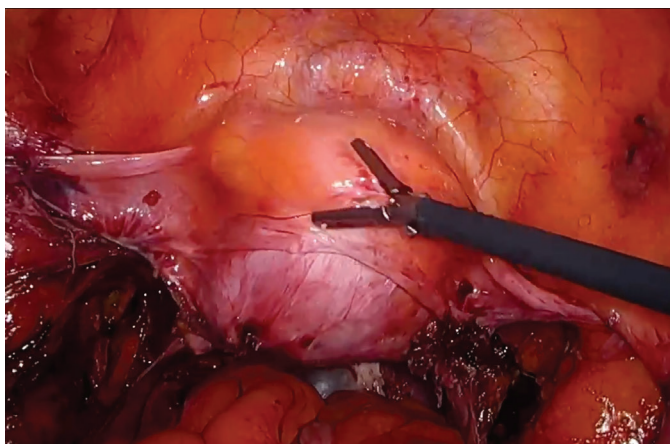


Figure 2. Cervical stump and bladder pushed with ring forceps inserted into the vagina

infundibulopelvic ligaments were ligated subsequent to the tracing of the bilateral ureteral tracts. The ligation of the bilateral uterine arteries was performed subsequent to the exiting from the internal iliac artery (Figure 1). Subsequently, the region of the cervicovesical region was meticulously exposed through a sharp dissection technique employing bipolar scissors (Figure 2). The bladder was then detached from the cervical stump. The cervical stump was meticulously separated from the vaginal cuff with the assistance of a tampon placed in the vagina, and was subsequently formed with ring forceps and a sponge (Figure 3). The cuff opening was closed by primary suturing.

Discussion

Secondary stumpectomy is a rare procedure performed following SH. The literature does not define the frequency for stumpectomy. Minimally invasive approaches may be applied. The three main indications for secondary cervical stump excision are: prolapse (31.4%); spotting (19.0%); and cervical dysplasia (18.2%) (1). Key differences between total laparoscopic hysterectomy and laparoscopic-assisted SH (LASH) include persistent vaginal bleeding (11-19%), de novo urinary incontinence (RR = 1.37), and the risk of cervical dysplasia and cervical cancer (1,2). However, patients who undergo LASH tend to return to daily activities more quickly, and sexual function outcomes are generally better. The interval between SH and secondary stumpectomy ranges from 34 to 113 months, depending on the indication. Unlike previously published cases, this case presents a unique scenario of persistent CIN 2 in a postmenopausal woman with a history of SH and HPV 16 positivity. While cervical stump neoplasia remains rare, recent studies report an incidence of up to 3%, often diagnosed late due to insufficient follow-up. In contrast, the present case highlights early surgical intervention based on patient preference and clinical reasoning, underscoring the importance of individualized management and long-term surveillance in this subset of patients (3).

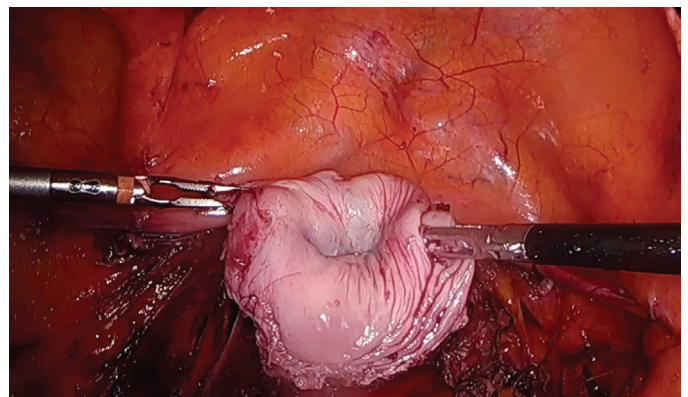


Figure 3. Cervix after separation from the vaginal cuff

Conclusion

Patients undergoing SH should be informed about the risks of spotting, cervical dysplasia, and cancer. This information may reduce the rates of SH. SH should not be performed in patients at risk for cervical dysplasia or cancer, such as those with high-risk HPV. The complication rate of stumpectomy is comparable to that of vaginal and laparoscopic hysterectomy. Careful screening of patients for SH and thorough counseling regarding the potential for incidental malignancy or premalignant conditions during SH are essential.

Video 1.



<http://dx.doi.org/10.4274/jtgga.galenos.2025.2025-4-5.video1>

Informed Consent: *Written informed consent was obtained for both the surgical procedure and the use of all relevant clinical data and video documentation for publication.*

Conflict of Interest: *No conflict of interest is declared by the authors.*

Financial Disclosure: *The authors declared that this study received no financial support.*

References

1. Andersen LL, Zobbe V, Ottesen B, Gluud C, Tabor A, Gimbel H; Danish Hysterectomy Trial Group. Five-year follow up of a randomised controlled trial comparing subtotal with total abdominal hysterectomy. *BJOG*. 2015; 122: 851-57.
2. Borendal Wodlin N. Intraoperative cervical treatment does not affect the prevalence of vaginal bleeding 1 year postoperatively after subtotal hysterectomy. A register study from the Swedish National Register for Gynecological Surgery. *Acta Obstet Gynecol Scand*. 2017; 96: 1430-37.
3. Wang J, Zeng X, Min L, Li L. Cervical stump cancer after subtotal hysterectomy: a retrospective research of 127 cases from china and literature review. *Clin. Exp. Obstet. Gynecol*. 2024; 51: 11.